



## Case Report

# Successful Root Canal Re-treatment of the Second Mandibular Premolar with type III of Vertucci Classification

Erma Sofiani<sup>1\*</sup>, Erwin Setyawan<sup>2</sup>

<sup>1</sup>Department of Conservative Dentistry, Faculty of Dentistry, Universitas Muhammadiyah Yogyakarta, Special Region of Yogyakarta, Indonesia

<sup>2</sup>Department of Dentomaxillofacial Radiology, Faculty of Dentistry, Universitas Muhammadiyah Yogyakarta, Special Region of Yogyakarta, Indonesia

Received date: October 5<sup>th</sup>, 2022; revised date: November 2<sup>nd</sup>, 2023; accepted: November 9<sup>th</sup>, 2023

DOI: 10.18196/di.v13i1.16418

## Abstract

Knowledge of the root canal system plays a significant role in avoiding the failure of root canal treatment. Premolar teeth may have several anatomical variations in their root canal system. A dentist must understand these root canal systems and their variation to conduct the appropriate treatment. The mandibular second premolar usually consists of a single root with a single root canal. The incidence of lower premolars with two or more root canals varied between 1.2% and 34%. This study aims to evaluate the success of root canal re-treatment of mandibular second premolars with type III Vertucci's Classification. Case report: A 28-year-old woman visited our dental hospital with a pain sensation in her lower left premolar tooth. The subjective examination revealed that she had experienced pulp capping and root canal treatment last year. However, she felt pain and uncomfortable feeling on that treated tooth. A radiograph examination showed a radiopaque area from the crown edge to half of the root. The radiolucent area from the half tooth to the apical region showed root canal branching. The diagnosis for this tooth was previously treated teeth, asymptomatic apical periodontitis with type III of Vertucci's Classification. Root Canal Treatment was done using crown down preparation technique and obturation with warm vertical condensation followed by class II composite resin composite as a temporary filling. Results showed that after three months of evaluation, the retreated-tooth condition kept showing good condition without any complaints, pain, or clinical abnormalities, suggesting it could function properly.

**Keywords:** crown-down technique; re-treatment; root canal treatment; vertucci's classification

## INTRODUCTION

The principles of root canal treatment include opening access, preparation, sterilization, and obturation. One of the successful root canal treatments is the knowledge of root canal anatomy and variations, along with clinical and radiographic examination of the tooth. The anatomy of the root canals varies greatly with each tooth, especially the posterior tooth.<sup>1</sup>

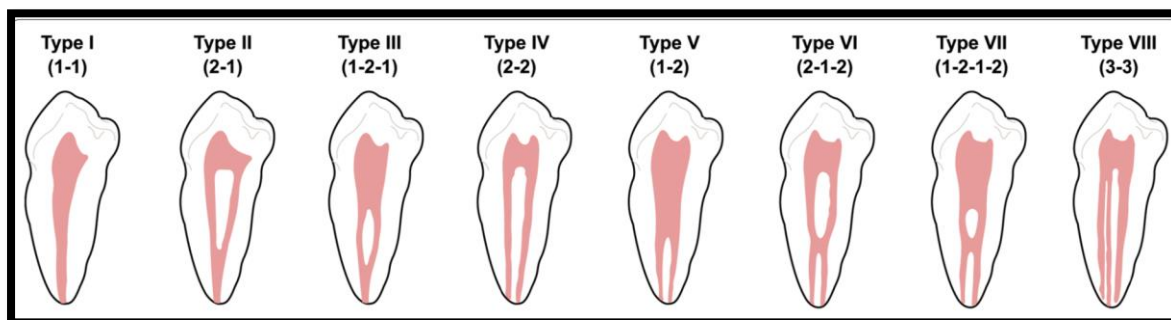
Root canal configurations were classified by Vertucci into 8 types (see Figure 1). Type I is a single canal extending

from the pulp chamber to the apex, and type II is two canals extending from the pulp chamber that merge into one canal before reaching the apex. Type III is one canal that extends from the pulp chamber, divides into two canals, and fuses into one canal before reaching the apex. Another configuration is type IV. Two canals extend from the pulp chamber to the apex. Type V is one canal extending from the pulp chamber into two canals before reaching the apex. Type VI is two canals extending from the pulp chamber that merge into one canal and then divides into two canal short to the apex.

\* Corresponding author, e-mail: [ermasofiani@umy.ac.id](mailto:ermasofiani@umy.ac.id)

Type VII is one canal that extends from the pulp chamber, divides, rejoins, and finally divides into two canals short of the apex.

Type VIII is three canals that extend from the pulp chamber to the apex.<sup>2,3</sup>



**Figure 1.** 8 Types of Root Canal Configuration by *Vertucci*

The premolar teeth are one of the teeth that have a considerable variation of root canal morphology. The incidence of root canal morphology variation in the mandibular first premolar teeth with one root canal at 74%, two root canals at 25.5%, and three root canals at 0.5%. Mandibular second premolar teeth had one root canal at 97.5% and two at 2.5%.<sup>4</sup> Kottor et al. (2013) research stated that the prevalence of mandibular first premolars with two roots and 3 or more root canals were 2.63% and 0-5%, respectively, while in mandibular second premolars, it was 0-4.4% and 0-5%, respectively.<sup>5</sup>

Common variations of anatomical configuration in the mandibular premolars are bifurcation, trifurcation, and C-shaped root canal. Prevalence of Vertucci type I is 63.1% and 98% in the mandibular first premolar and second premolar, respectively. Type II of Vertucci Configuration, Type III of Vertucci's Classification is rare because one canal leaves the pulp chamber and is divided into smaller ones that merge again to exit through one canal. Type III vertucci are 2.6 % and 0.4% prevalence in the mandibular first and second premolars, respectively.<sup>3</sup> The other research stated that the incidence of mandibular second premolars with two root canals and two apical foramina was only 11.5%, while that of mandibular first premolars with branching canals, apical bifurcations, and trifurcations was 26.5%.<sup>5</sup>

Another study showed that the prevalence of bifurcation (type V, 1.2) was 28.5% and 1.5% in the mandibular first and second premolar, respectively. A higher incidence of bifurcation, such as type V of vertucci, was reported in India, Kuwait, Jordan, and Turkey. A C-shaped root canal was present in 0,6% of mandibular second premolars and 1-18% of mandibular first premolars.<sup>6,7</sup> The prevalence of a C-shaped root canal was 0.7% in the mandibular second premolar, the high prevalence of C-shaped root canals found in the Chinese population.<sup>6</sup>

A trifurcation has a prevalence of 0,4-5% in the mandibular first premolar and 0,4% in the mandibular second premolar. Another study showed that trifurcation was 3.2% in the Thai population.<sup>3,6</sup>

According to Ingle, several factors influence the variation of root canals in teeth, namely race, age, sex, and type of teeth.<sup>7</sup> The presence of root canal variation will determine the success of a dentist in performing debridement so that treatment will cause flare-ups before or after treatment. Dentists must also have interpretation capabilities in periapical radiography as one of the keys to successful treatment.<sup>8</sup>

Failure of root canal treatment is due to inadequate biomechanical preparation, non-hermetic obturation, and non-cleansed root canals that will cause pain.<sup>9</sup> Inadequate preparation is caused by a

failure to detect a missed canal. The high failure rate of mandibular first premolar is 11.45%.<sup>10</sup>

The previous study examined root canal configuration using two-dimensional periapical radiographs or three-dimensional cone-beam computed tomography (CBCT).<sup>11</sup>

In this case, it has a previously treated teeth diagnosis accompanied by periodontitis periapical symptomatic. Post-treatment pain caused by microorganisms in root canals remains behind so conventional re-treatment can be done.

The objective of this study was to report and evaluate root canal re-treatment in the case of mandibular second premolars of Vertucci type III with periodontitis periapical symptomatic.

## CASE REPORT

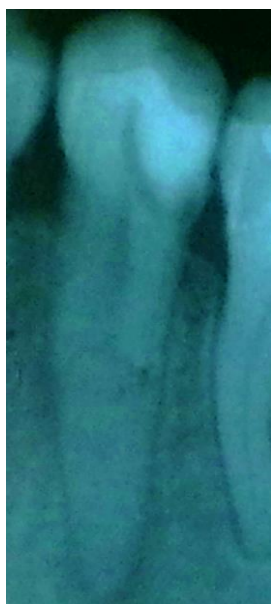A 26-year-old woman came with complaints of toothache for the past three years. The previous dentist carried out a history of cavities two years ago, and then the pulp capping treatment was carried out one year ago. A few months later, the tooth had spontaneous pain, especially when chewing food and being touched by the contralateral tooth.

An objective examination of tooth 35 (see Figure 2, Figure 3, Figure 4, Figure 5) revealed discolored composite resin fillings on the distoocclusal surface, percussion (+), and palpation (-). The periapical radiograph showed a radiopaque area on the tooth's crown up to the half of the root canal (non-

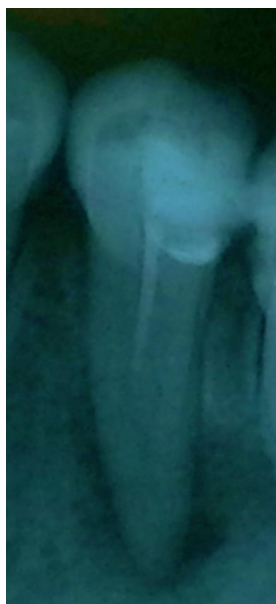hermetic filling) and a radiolucent area with a diffuse border on the periapical area of the tooth. The diagnosis in this case is previously treated teeth with symptomatic periapical periodontitis, and the differential diagnosis is a chronic periapical abscess. There is a good prognosis for this case if a re-treatment of the root canal and then a permanent restoration is performed.

In the first visit, the composite resin filling was removed, taking gutta-percha with gates glidden drill #1 and irrigating with 2.5% NaOCl. Furthermore, the tooth was explored using #10 K-File, pulp extirpation, and root canal irrigation. During root canal exploration, two root canals were fused apically, and the apex locator measured and confirmed the working length (*Propex Pixi, Dentsply Sirona*). The working length was 20.5 mm. At the next visit, root canal preparation was carried out using the crown down technique using Protaper (*Dentsply Sirona*) hand use until F2 and 2.5% NaOCl irrigation and root canal sterilization using low-setting calcium hydroxide (Metapaste, Meta Biomed).

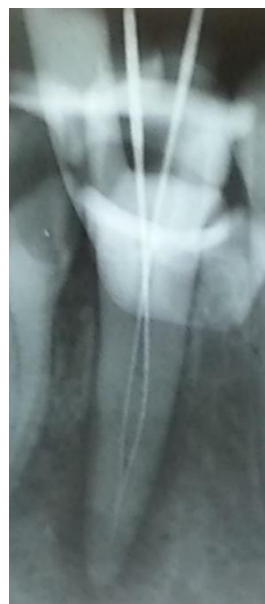Two weeks later, the patient came to continue the post-sterilization treatment of the root canal. Subjective examination showed no complaints of pain; the objective examination was percussion and palpation (-); the teeth were asymptomatic. Then, obturation of the root canal was performed with the single cone technique, and the temporary filling was performed with GC Fuji IX GP Capsule (*GC Corp, America*).



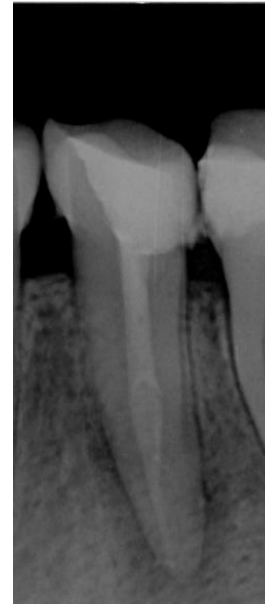
**Figure 2.**  
#35 post pulp capping  
(preoperative 1)



**Figure 3.**  
#35 post inadequate RCT



**Figure 4.**  
#35 Working length



**Figure 5.**  
#35 After 1 month of control

One week after obturation, control one was performed. On objective and subjective examination, there were no complaints of pain, and then sandwich restoration was performed as a temporary filling before full crown restoration. In the second control, after one month of subjective and objective examination, the teeth were asymptomatic and functioning well. Radiographic examination revealed a radiopaque area in the root canal and radiolucency in the apical area that narrowed, indicating the healing process. The next plan will be to restore the full crown with a prefabricated dowel (fiber post).

## DISCUSSION

This case aims to evaluate the success of root canal re-treatment of mandibular second premolars with type III Vertucci root canals with chronic periapical abscess. The treatment planning of this case is root canal re-treatment and full crown restoration with prefabricated dowel posts (fiber post) so that the teeth can function esthetically, phonetically, masticate and protect the supporting tissues.

Premolars are one of the posterior teeth that function to chew food, so they have a more significant chewing load than the anterior teeth. In this case, the teeth involved were mandibular second premolars, the majority of which had one root, one root canal, and a thickness of the root canal. Rare anatomy is a mandibular second premolar with a single root canal dividing into two separated canals and then fusing in the apex. Mandibular second premolars sometimes have difficulty in root canal treatment. It is due to the complexity of internal anatomy, such as the number of roots, root canals, race, and gender. Knowledge of root canal anatomy is essential in root canal treatment, for it is necessary to understand the interpretation of radiographs well so that root canal treatment fails. The inability to locate, debride, and fill all canals has been reported to be the major cause of failure for root canal treatment.<sup>12,13</sup>

Furthermore, the most common root canal configuration was Vertucci type I, with a 63.1% and 98% prevalence in the mandibular first and second premolars, respectively. Although most mandibular first and second premolars were categorized

as Type I of Vertucci, we found that the mandibular second premolars were also categorized as Type III of Vertucci, only 0.4% of the Thai population.<sup>6</sup> In this case, the mandibular second premolars had two root canals according to the Vertucci type III classification. The root canals were 2 to two-thirds of the coronal and fused in the apical third.<sup>8</sup> The previous study reported the percentage of Vertucci type III as 4.35% in the Turkish population and 11.6% in the Indian population.<sup>14</sup>

The incidence of mandibular second premolar with two root canals was 11.7 %, 0.1-0.4%, with three root canals. The incidence of multiple roots and canals in the mandibular second premolar is lower than the mandibular first molar, with the root canal configuration of the mandibular second premolar at 9,9% and the mandibular first premolar at 24%.<sup>15</sup> The study of Trope et al. reported the anatomical incidence of mandibular second premolar root canals with two or more root canals in Caucasian Negroid races of 7.8% versus 2.8%. A population study in Saudi Arabia has found that teeth with Vertucci types I and V have a higher prevalence in women than men, while teeth with Vertucci type III have a higher prevalence in men.<sup>16</sup> Vertucci (1984) reported that mandibular second premolars with one root canal incidence was 97.5%, two root canals were only 2.5%, and three were rare.<sup>2</sup> Another study stated that the incidence of multiple root canals in mandibular first premolars was 19.48%, and in mandibular second premolars, 3.85%.<sup>17</sup>

In root canal treatment, a clinician must understand the anatomical variations of the root canal. The first step that must be done is identification and negotiation. Therefore, a radiographic examination is mandatory. Conventional radiographs are still often used in root canal treatment but are not accurate enough to detect root canal variations as superimposition of images often occurs. Therefore, complex root canal anatomy cases limit two-dimensional periapical radiographs' use and value. To

get a better and more accurate interpretation, it is necessary to use CBCT/three-dimensional imaging.<sup>16</sup> In other cases, the CBCT system should be prioritized with anatomical variations to help establish the diagnosis.<sup>18</sup>

The success of root canal treatment is strongly influenced by clinical examination, correct diagnosis, and adequate biomechanical preparation and filing of all root canal systems. The inability to define root canals and clean and fill all root canal systems is a significant failure in treatment.<sup>12</sup>

The root canal preparation technique used in this case was the crown-down technique. The advantage of this technique is that the preparation starts from coronal to apical so that debridement is maximized due to good coronal flaring. Irrigation materials can also work optimally in eliminating bacteria in the root canal. The Crown Down Technique, in this case, used a Pro taper as the geometric shape is convex, triangular cross-section. It progressively tapered pro taper file design so files were more flexible, and dentin reduction was effective and safer.<sup>19</sup>

Treatment of mandibular second premolars should not be considered easy due to the many variations of root canals, so clinicians must always be aware of anatomical variations for root canal treatment to succeed. Several tools, such as a microscope, loop, apex locator, and CBCT imaging, facilitate root canal treatment. Re-root canal treatment in the above case was successful based on clinical and radiographic evaluation, so the tooth remained functional in its arch.<sup>20</sup>

The limitation of this case report is that a long-term evaluation of at least 1 year after an ideal restoration is carried out so that it can see the healing of periapical lesions. In the study of Kanmaz (2017), the healing of periapical lesions was 74% in 42 teeth, occurring 1-12 months after root canal treatment. Periapical lesion healing can be assessed with the Periapical Index (PAI).<sup>21</sup>

## CONCLUSION

Re-treatment with symptomatic apical periodontitis and Vertucci type III classification in the case was successful as the tooth was asymptomatic clinically and radiographically after being evaluated for 3 months.

## REFERENCE

1. Karobari MI, Parveen A, Mirza MB, Makandar SD, Nik Abdul Ghani NR, Noorani TY, et al. Root and root canal morphology classification systems. *Int J Dent*. 2021;2021:1–6. <http://dx.doi.org/10.1155/2021/6682189>
2. Vertucci FJ. Root canal anatomy of the human permanent teeth. *Oral Surg Oral Med Oral Pathol*. 1984;58(5):589–99. [http://dx.doi.org/10.1016/0030-4220\(84\)90085-9](http://dx.doi.org/10.1016/0030-4220(84)90085-9)
3. Vertucci FJ. Root canal morphology of mandibular premolars. *J Am Dent Assoc*. 1978;97(1):47–50. <http://dx.doi.org/10.14219/jada.archive.1978.0443>
4. Molyvdas I, Digka A, Mikrogeorgis G. Root canal treatment of mandibular second premolars with three root canals: Report of four rare cases. *Balkan J Dent Med*. 2020;24(3):49–52. <http://dx.doi.org/10.2478/bjdm-2020-0008>
5. Kottoor J, Albuquerque D, Velmurugan N, Kuruvilla J. Root anatomy and root canal configuration of human permanent mandibular premolars: A systematic review. *Anat Res Int*. 2013;2013:1–14. <http://dx.doi.org/10.1155/2013/254250>
6. Thanaruengrong P, Kulvitit S, Navachinda M, Charoenlarp P. Prevalence of complex root canal morphology in the mandibular first and second premolars in Thai population: CBCT analysis. *BMC Oral Health*. 2021;21(1). <http://dx.doi.org/10.1186/s12903-021-01822-7>
7. Wolf TG, Anderegg AL, Wierichs RJ, Campus G. Root canal morphology of the mandibular second premolar: a systematic review and meta-analysis. *BMC Oral Health*. 2021;21(1). <http://dx.doi.org/10.1186/s12903-021-01668-z>
8. Martins JNR, Francisco H, Ordinola-Zapata R. Prevalence of C-shaped configurations in the mandibular first and second premolars: A cone-beam computed tomographic in vivo study. *J Endod*. 2017;43(6):890–5. <http://dx.doi.org/10.1016/j.joen.2017.01.008>
9. Ring J, Ring KC. Rare root canal configuration of mandibular second premolar using cone-beam computed tomographic scanning. *J Endod*. 2017;43(11):1897–900. <http://dx.doi.org/10.1016/j.joen.2017.04.023>
10. Baruwa AO, Martins JNR, Meirinhos J, Pereira B, Gouveia J, Quaresma SA, et al. The influence of missed canals on the prevalence of periapical lesions in endodontically treated teeth: A cross-sectional study. *J Endod*. 2020;46(1):34-39.e1. <http://dx.doi.org/10.1016/j.joen.2019.10.007>
11. Alshammari SM, Ganji KK, Albulayhid AA, Alshammari AM, Alhassan KHR, Alsirhani MAR. Prevalence of second root and root canal in mandibular and maxillary premolars based on two classification systems in sub-population of northern region (Saudi Arabia) assessed using Cone beam computed tomography (CBCT): A retrospective study. *Diagnostics (Basel)*. 2023;13(3):498. <http://dx.doi.org/10.3390/diagnostics13030498>
12. Induja MP, Chokkattu JJ. Root canal morphology of mandibular premolars: CBCT analysis. *Int J Health Sci (IJHS)*. 2022;11936–43. <http://dx.doi.org/10.53730/ijhs.v6ns2.8222>
13. Shah SA. Endodontic management of mandibular second premolar with

- Vertucci root canal configuration type V. *Case Rep Dent.* 2022;2022:1–7. <http://dx.doi.org/10.1155/2022/3197393>
14. Somalinga Amardeep N, Raghu S, Natanasabapathy V. Root canal morphology of permanent maxillary and mandibular canines in Indian population using cone beam computed tomography. *Anat Res Int.* 2014;2014:1–7. <http://dx.doi.org/10.1155/2014/731859>
  15. Cleghorn BM, Christie WH, Dong CCS. The root and root canal morphology of the human mandibular first premolar: A literature review. *J Endod.* 2007;33(5):509–16. <http://dx.doi.org/10.1016/j.joen.2006.12.004>
  16. From editor's desk. *Int J Epilepsy.* 2016;03(01):001. [http://dx.doi.org/10.1016/s2213-6320\(16\)30016-1](http://dx.doi.org/10.1016/s2213-6320(16)30016-1)
  17. Arayasantiparb R, Banomyong D. Prevalence and morphology of multiple roots, root canals and C-shaped canals in mandibular premolars from cone-beam computed tomography images in a Thai population. *J Dent Sci.* 2021;16(1):201–7. <http://dx.doi.org/10.1016/j.jds.2020.06.010>
  18. Rodríguez G, Patel S, Durán-Sindreu F, Roig M, Abella F. Influence of cone-beam computed tomography on endodontic retreatment strategies among general dental practitioners and endodontists. *J Endod.* 2017;43(9):1433–7. <http://dx.doi.org/10.1016/j.joen.2017.04.004>
  19. C.J. Ruddle, Ch.8 Cleaning and Shaping Root Canal Systems, In S.Cohen and R.C. Burns : *Pathway of the Pulp*, pp. 231-291, 12<sup>th</sup> ed., Cohen and Burns, Mosby, St. Louis, 2021.
  20. Chybowski EA, Glickman GN, Patel Y, Fleury A, Solomon E, He J. Clinical outcome of non-surgical root canal treatment using a single-cone technique with endosequence bioceramic sealer: A retrospective analysis. *J Endod.* 2018;44(6):941–5. <http://dx.doi.org/10.1016/j.joen.2018.02.019>
  21. Kanmaz F, Altunbaş D, Zan R, Akpınar KE. Nonsurgical Endodontic Treatment of a Large Periradicular Lesion. *Turk Endod J* 2017;2(1):21–24 [https://www.journalagent.com/tej/pdfs/TEJ\\_2\\_1\\_21\\_24.pdf](https://www.journalagent.com/tej/pdfs/TEJ_2_1_21_24.pdf)